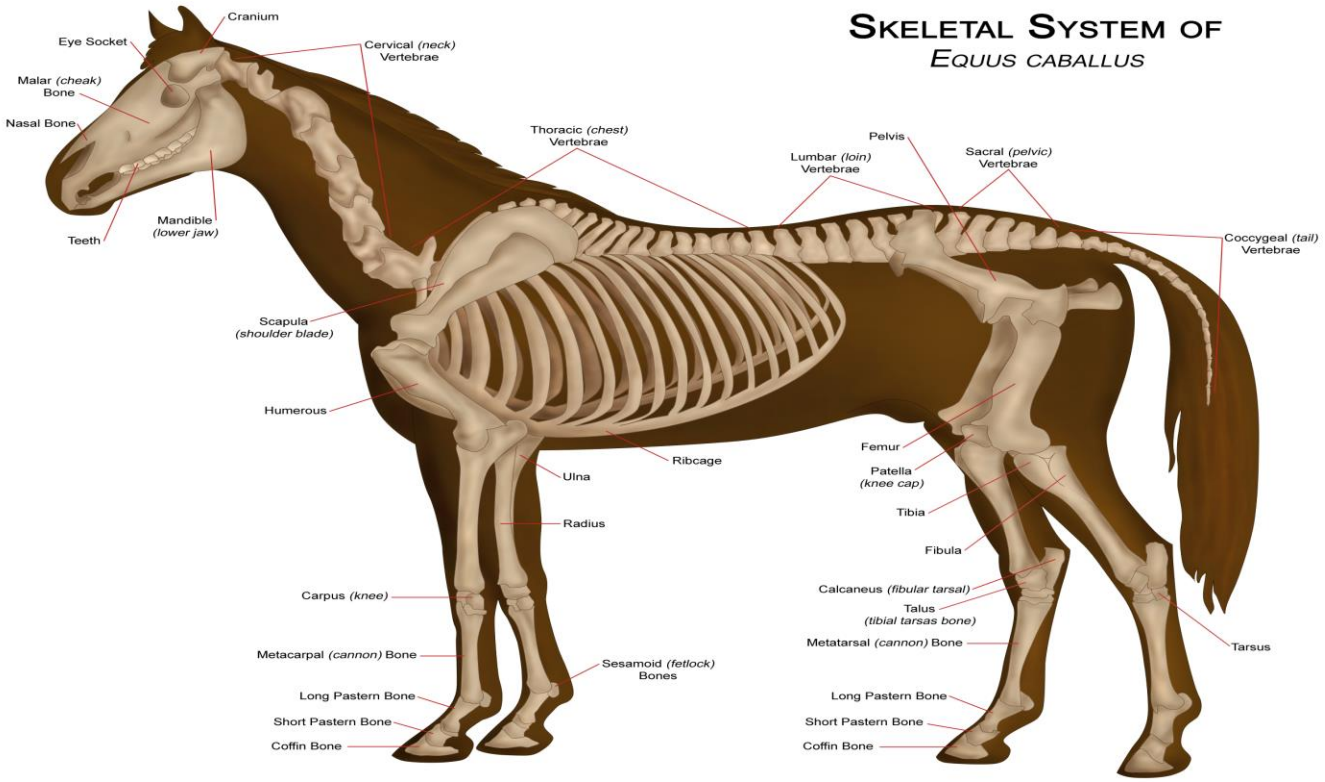
Skeletal System of
Equus caballus
Cranium
Eye Socket
Cervical (neck) Vertebrae
Malar (cheak) Bone
Nasal Bone
Thoracic (chest) Vertebrae
Pelvis
Lumbar (loin) Vertebrae
Sacral (pelvic) Vertebrae
Mandible (lower jaw)
Teeth
Coccygeal (tail) Vertebrae
Scapula (shoulder blade)
Humerous
Ribcage
Femur
Patella (knee cap)
Ulna
Tibia
Radius
Fibula
Calcaneus (fibular tarsal)
Carpus (knee)
Talus (tibial tarsas bone)
Metatarsal (cannon) Bone
Tarsus
Metacarpal (cannon) Bone
Sesamoid (fetlock) Bones
Long Pastern Bone
Short Pastern Bone
Coffin Bone
Long Pastern Bone
Short Pastern Bone
Coffin Bone

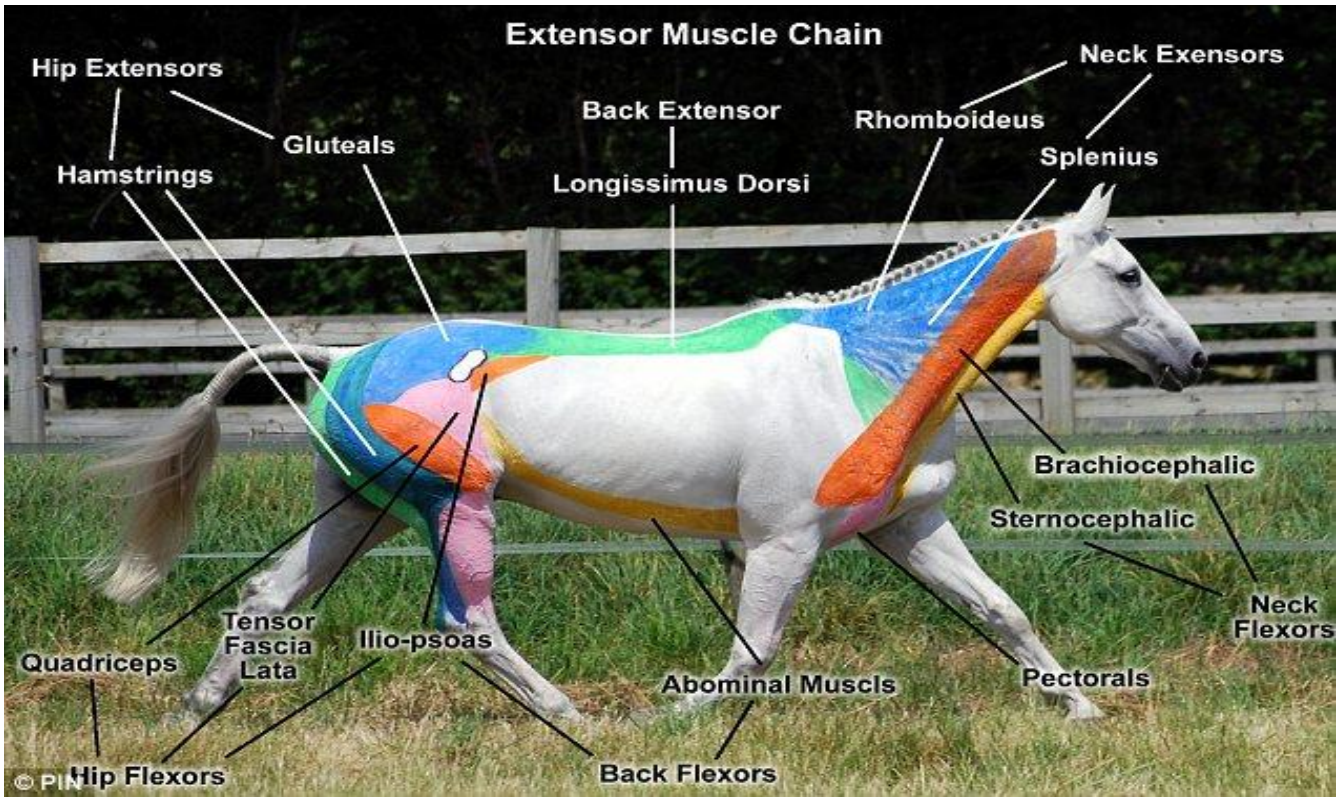
Extensor Muscle Chain
Hip Extensors
Neck Exensors
Back Extensor
Rhomboideus
Gluteals
Splenius
Hamstrings
Longissimus Dorsi
Brachiocephalic
Sternocephalic
Neck Flexors
Tensor Fascia Lata
Ilio-psoas
Quadriceps
Abominal Muscls
Pectorals
Hip Flexors
Back Flexors
© PIN